

OUR EXPERIENCE WITH A 3D MESH IN THE MANAGEMENT OF RECTAL PROLAPSE

VLČEK P.¹, KORBIČKA J.¹, CHALUPNÍK Š.¹, JEDLIČKA V.¹, VEVRKOVÁ L.¹, ČAPOV I.¹, WECHSLER J.¹, VLČKOVÁ P.², DOLINA J.², BARTŮŠEK D.³

¹First Department of Surgery, St. Anne's Faculty Hospital, Brno

²Department of Gastroenterology, Faculty Hospital Brno

³Department of Radiology, Faculty Hospital Brno

Received after revision May 2006

Abstract

A variety of surgical procedures have been developed to treat rectal prolapse, but there is still no consensus on the operation of choice. The aim of this study was to evaluate the functional results of operative treatment of rectal prolapse during a 3-year period in our department.

All patients treated for complete rectal prolapse from January 1999 to September 2003 were included. Of the 14 patients, 9 were men, and the mean age was 59 /range 40-88/.

The majority of the procedures were performed by abdominal approach, and the most frequently used open technique was anterior rectopexy with a mesh /3D/. Of the incontinent patients, 82% were continent postoperatively. The proportion of patients with constipation was greater after the operation than preoperatively. In our group there was only 1 recurrent prolapse.

Anterior rectopexy with mesh gave good results. Older age seems to have a negative effect on the functional outcome of the operation.

Key words

Rectal prolapse, 3D mesh, Rectopexy

INTRODUCTION

Complete rectal prolapse /proctidentia/ is the circumferential protrusion through the anus of all layers of the rectal wall. It is most common in young children and elderly adults. Rectal prolapse or proctidentia is a disabling problem and controversies regarding its management continue to stimulate interest in the study of its aetiology, pathophysiology, functional aspects, and concepts of surgical management.

Aetiology. The underlying cause of rectal prolapse remains unclear. It is thought to develop as the result of a series of functional disturbances in muscles of the anterior abdominal wall, pelvic floor, and anal sphincter complex (1,3), which creates an initial inversion of the upper rectum towards the anal canal (2,5). These underlying abnormalities may be aggravated by certain conditions which appear to be

associated with an increased incidence of rectal prolapse. These include connective tissue disorders /3/, neurological illnesses (4), and high parity (5).

Pathophysiology. The pathophysiology of rectal prolapse was first described in the late 19th century, long before abdominal surgery was considered safe. The early operations were perineal procedures, one of which is the Mikulicz procedure /perineal rectosigmoidectomy/, first performed in 1889. However, the aetiopathology of rectal prolapse remained unknown until 1912 when Moschcowitz proposed the theory of a sliding hernia through a defect in the pelvic fascia as a cause of rectal prolapse. His theory was based on the presence of a deep rectovesical or rectovaginal pouch in most patients with a complete procidentia. He then went on to describe the Moschcowitz procedure, which involved obliteration of the peritoneal pouch of Douglas by a purse-string. The recurrence rate was, however, 80 per cent (6-10).

Broden and Snellman in 1968 discounted Moschcowitz's theory and put forward the concept of a circumferential intestinal intussusception; the authors demonstrated this phenomenon through cineradiography (11,12). Porter in 1962 reported that reflex inhibition of the external sphincter and levator muscles with distension of the rectum was more profound and prolonged in patients with rectal prolapse. Parks et al. in 1977 showed that mean resting pressures were maintained in those with rectal prolapse, suggesting a dysfunction of the internal sphincter as a cause of prolapse (13,14).

There are many other conditions found in association with rectal prolapse. One such association is a connective tissue disorder. Marshman et al. in 1987 reported that many patients had an associated increased joint mobility (3). Other associated factors with rectal prolapse include mental illness, neurological disorders, and parity. Corman described nulliparous women as having the greatest risk of developing rectal prolapse (13).

There is considerable controversy about the cause of rectal prolapse - associated incontinence. Keighley and Shouler demonstrated an increase in sigmoid motility in incontinent patients with prolapse, while continent patients had normal sigmoid motility but delayed whole gut transit. The authors therefore suggested an increase in bowel motility as a cause of prolapse-associated incontinence (1,8).

Matheson and Keighley found a significantly decreased resting and squeeze anal pressure in incontinent patients with prolapse, but normal pressures in continent patients (1,14).

Gordon found evidence of denervation of the puborectalis and external sphincter muscles in incontinent patients. Farouk et al. suggested that repair of rectal prolapse probably allows the internal anal sphincter to recover by removing the cause of persistent rectoanal inhibition (13).

Duthie and Bartolo claimed recently that the recovery of continence after operation does not depend on sphincter recovery but on improved anorectal sensation (14).

Delamarre et al. found an increase in rectal compliance and capacity after surgery in patients treated successfully for rectal prolapse and incontinence (15).

The association of constipation with rectal prolapse has been reported to vary from 25 to 50 per cent. The exact cause of constipation is, again, controversial and poorly understood. *Metcalf* and *Loening-Baucke* demonstrated a paradoxical increase in external anal sphincter electromyographic activity in those with rectal prolapse who were constipated. Some authors, however, have attributed constipation to a delay in colonic transit (9). *Speakman et al.* recently showed in a prospective randomised trial that division of the lateral ligaments during rectopexy caused constipation, although it prevented the recurrence of rectal prolapse (10).

The management of rectal prolapse is usually surgical. Surgical approaches for rectal prolapse can be classified into either transabdominal or perineal.

Perineal procedures were first used in the late 19th century as abdominal surgery was then considered unsafe. *Moschcowitz* first described the obliteration of the peritoneal pouch of Douglas based on the fact that rectal prolapse is commonly associated with an abnormally deep cul-de-sac. However, recurrence rates as high as 80 per cent have been reported.

Anal encirclement was first described in 1891 by *Thiersch*. Advantages of this procedure included simplicity, repeatability, and that it required only a local anaesthetic. However, anal encirclement does not cure the disease process (1).

Mikulicz first described perineal rectosigmoidectomy in 1889 and the procedure was repopularised in the 1960s by *Altemeier* and colleagues. This procedure is based on fixing the bowel to the sacrum by fibrosis around the anastomosis. The recurrence rates have been reported from 0 to 50 per cent (8).

The Delorme operation is a modification of perineal rectosigmoidectomy in which the prolapsed bowel is not resected; its mucosa is stripped and the muscularis propria of the rectum and sigmoid are plicated and replaced above the levator muscles. Recurrence rates ranging from 5 to 21 percent have been reported (15).

Abdominal procedures for rectal prolapse usually involve rectal fixation, large bowel resection or a combination of both. Rectal fixation, or rectopexy, which was first described by *Pemberton* and *Stalker*, involves full rectal mobilisation followed by fixation of the rectum to the sacrum. Most surgeons use a foreign material to help anchor the rectum to the sacrum.

The Ripstein procedure is one of the most commonly used rectal fixation operations. It involves completely wrapping the mobilised rectum with a foreign material and suturing it to the sacrum. The possible complications include erosion of the foreign material and fistula formation and stenosis. Some authors have reported that foreign material is not important in the provocation of an intense fibrous tissue formation, and have shown that sutures alone are sufficient and allow equally low recurrence rates of 0–4 per cent (17,18). Anterior resection has also been described in the treatment of rectal prolapse. The principle in this case is the creation of fibrosis between the anastomosis and the sacrum. A major disadvantage of this procedure,

however, includes a possible decrease in continence secondary to a decrease in the rectal reservoir (15,16, 9).

A combined colonic resection and rectopexy is also commonly performed. This makes use of the advantages of resection and avoids the disadvantages of rectopexy alone, especially with regard to constipation. Generally, resection rectopexy is reserved for patients who have a history of severe constipation.

The use of laparoscopic techniques in the surgical treatment of rectal prolapse has been advocated as having several attractive features. Mobilisation of the rectum laparoscopically has been shown to be safe and feasible.

MATERIALS AND METHODS

Selection of the most appropriate surgical operation continues to be problematic for the surgeon. In our institution we prefer anterior rectopexy with the use of a three-dimensional mesh. One must remember that success in the management of rectal prolapse is not simply the correction of the physical and mechanical abnormality - functional aspects are also important. The ideal surgical technique should, therefore, be based not only on the elements of simplicity, recurrence and complications, but should also take into account the treatment or at least alleviation of the functional disorder so commonly associated with rectal prolapse.

Fourteen adult patients with complete rectal prolapse underwent operative treatment for the prolapse between January 1999 and September 2003 in 1st Dept. of Surgery of the St. Anne's Faculty Hospital. Nine patients were men, and the mean age was 59 /range 40-88/. Two patients had previously undergone operations for rectal prolapse and two patients had previously undergone two gynaecological operations /hysterectomies/. We used Holzschneider's incontinence score for grading anal incontinence. All patients treated by abdominal approach were given preoperatively an enema /Yal/. Antibiotic prophylaxis was given before the operation /Normix, Alfa Wassermann/. Our technique of abdominal anterior mesh rectopexy was as follows: Through a low midline incision, the rectum was mobilised to the tip of coccyx, and the lateral ligaments were ligated. A 3D PET /polyethylene terephthalate/ mesh 10x15 cm with three-dimensional <<honeycomb>> structure /HiTec/ was sutured to the presacral fascia immediately below the promontory by Pro-Tack stapler /AutoSuture/ or Endo-anchor system /Ethicon/. The mobilised rectum was pulled straight, and the mesh was sutured onto the rectum. The peritoneum was closed over the mesh (Figs. 1, 2, 3).

The patients were followed up by clinical examination at a mean of ten /range, 6-20/ months after the operation for posterior mesh rectopexy or fourteen /range, 4-32/ months after the operation for anterior mesh rectopexy. During the follow-up period one anterior mesh rectopexy was performed in the posterior mesh group.

RESULTS

The surgical techniques used in treating rectal prolapse in 14 patients over a 45-month period are shown in *Table 1*. All procedures were performed by abdominal approach, and the most frequently used open technique was anterior rectopexy with a mesh. Eleven of 14 patients had preoperatively suffered some degree of anal incontinence. Of these incontinent patients, 9 regained continence postoperatively, leaving 2 patients with some degree of incontinence. Three patients had constipation preoperatively as compared with 6 patients postoperatively. The proportion of patients with constipation was greater after the operation than preoperatively. Accordingly, more



Fig. 1
3-D mesh with three-dimensional <honeycomb> structure

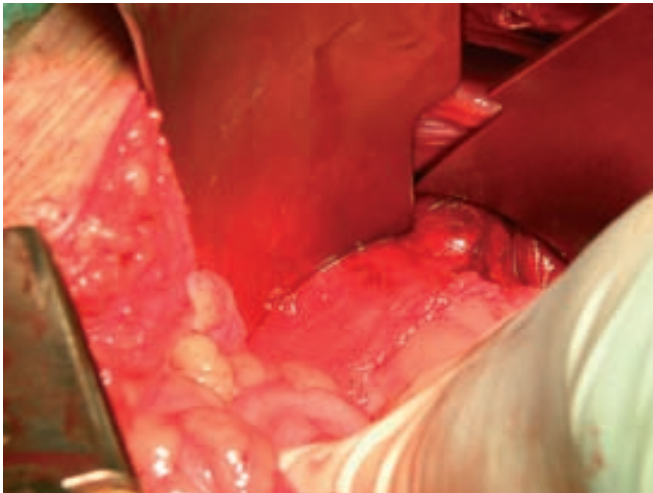


Fig. 2
Mobilisation of the rectum

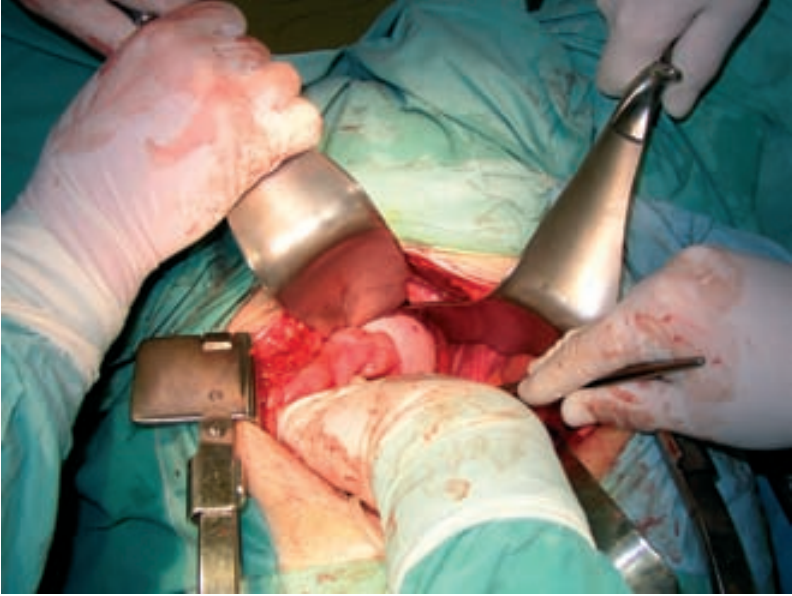


Fig. 3
Suturing the mesh onto the rectum after using Pro - Tack

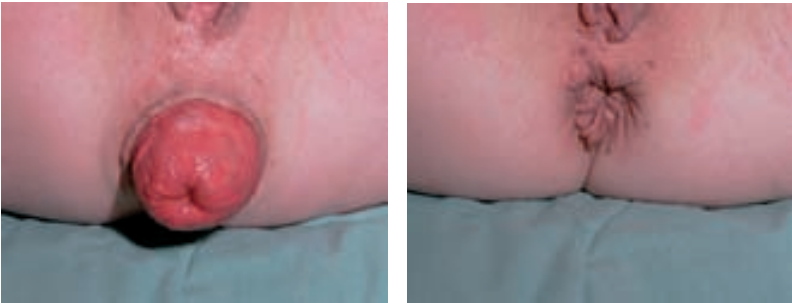


Fig. 4
Preoperative and postoperative situation

patients used medication for constipation after than before the operation, but the patients claimed less severe emptying problems after the operation (*Table 2*). Two less severe complications following abdominal rectopexy were successfully managed conservatively /small bowel obstruction and wound infection/. One case of recurrence after posterior mesh rectopexy was successfully managed by reoperation /anterior mesh rectopexy/ - *Table 3*.

Table 1
Techniques Used in Treating Complete
Rectal Prolapse in 12 Patients in 3-Year Period

Operative technique	Number of patients (%)	Mean age, yr. (range)
Posterior mesh rectopexy	3 (21)	62 (40-88)
Anterior mesh rectopexy	9 (79)	58(52-78)

Table 2
Functional Outcome After Surgical Treatment of
Rectal Prolapse

	Posterior mesh rectopexy (n=3)	Anterior mesh rectopexy (n=11)
Follow-up time (months)	10(6-20)	14(4-32)
Constipation		
Preoperative	1	2
Postoperative	2	4
Incontinence		
Preoperative		
None	1	2
Relative	2	7
Absolute	0	2
Postoperative		
None	2	9
Relative	1	1
Absolute	0	1

Table 3
Complications Related to Abdominal Rectopexy
(14 Patients)

Type of complication	No. of events
Recurrence	1 (PMR)
Pulmonary	0
Cardiac	0
Wound infection	1
Stricture	0
Small bowel obstruction	1
Sexual dysfunction	0
Incisional hernia	0
Total	1 recurrence, 2 other events in 12 patients

CONCLUSION

The choice of an ideal operation for complete rectal prolapse remains a perplexing problem for the surgeon. At our institution we prefer anterior mesh rectopexy with a 3-D mesh, also for older patients. One has to remember that success in the management of rectal prolapse is not simply the correction of the physical or mechanical abnormality; functional aspects are also important. The ideal surgical technique should, therefore, be based not only on the elements of simplicity, recurrence and complications, but should also take into account the treatment or at least alleviation of the functional disorder so commonly associated with rectal prolapse.

Acknowledgement

Supported by grant IGA MZ, No. ND7468-3/2003 A preliminary report of this study was presented at the ECCP meeting, Athens, Greece, May 28 to June 3, 2003.

Vlček P., Korbička J., Chalupník Š., Jedlička V., Veverková L., Čapov I., Wechsler J., Vlčková P., Dolina J., Bartůšek D.

NAŠE ZKUŠENOSTI S VYUŽITÍM 3-D SÍTKY PŘI ŘEŠENÍ PROLAPSU REKTA

S o u h r n

Mezi mnoha chirurgickými metodami korigujícími prolaps rekta není zatím jednoznačná metoda volby. Cílem naší studie bylo zhodnocení funkčních výsledků chirurgické léčby prolapsu rekta během tříletého intervalu na naší klinice.

Do studie byli zahrnuti pacienti operovaní na naší klinice pro kompletní prolaps rekta od ledna 1999 do září 2003. Z těchto 14 pacientů bylo 9 mužů s průměrným věkem 59 let /40–88 let/.

Většina operačních výkonů byla provedena transabdominálně a nejpoužívanější metodou byla přední rektopexie dle Ripsteina s využitím 3-D sítky. Mezi pacienty s předoperačně zjištěnou inkontinencí došlo u 82 % k podstatnému zlepšení. Naopak počet pacientů s obštipací po operaci se zvětšil. V celé skupině jsme pozorovali 1 recidivu.

Za metodu volby při řešení kompletního prolapsu rekta považujeme přední rektopexi dle Ripsteina. U starších pacientů pokládáme věk za negativní faktor ovlivňující funkční výsledek operace.

REFERENCES

1. *Eu KW, Seow-Choen F.* Functional problems in adult rectal prolapse and controversies in surgical treatment. *Brit J Surgery* 1997; 84(7): 904–11.
2. *Theuerkauf FJ Jr, Beahrs OH, Hill JR.* Rectal prolapse. Causation and surgical treatment. *Annals of Surgery* 1970; 171(6): 819–35.
3. *Marshman D, Percy J, Fielding I, Delbridge L.* Rectal prolapse: relationship with joint mobility. *Australian and New Zealand Journal of Surgery* 1987; 57(11): 827–9.
4. *Schoetz DJ, Veidenheimer MC.* Rectal prolapse. Pathogenesis and clinical features. In: Henry MM, Swash M, eds. *Coloproctology in the pelvic floor*. London: Butterworths, 1985.
5. *Karasick S, Spetell CM.* The role of parity and hysterectomy on the development of pelvic floor abnormalities revealed by defecography. *American Journal Roentgenology* 1997; 169(6): 1555–8.
6. *Aitola PT, Hiltunen KM, Matikainen MJ.* Functional results of operative treatment of rectal prolapse over an 11-year period: emphasis on transabdominal approach. *Dis Colon Rectum* 1999; 42: 655–660.
7. *Jacobs LK, Lin YJ, Orkin BA.* The best operation for rectal prolapse. *Surg Clin North Am* 1997; 77: 49–71.
8. *Keighley MR, Fielding JW, Alexander-Williams J.* Results of Marlex mesh abdominal rectopexy for rectal prolapse in 100 consecutive patients. *Brit J Surgery* 1983; 70: 229–232.
9. *Tjandra JJ, Fazio VW, Church JM, Milsom JW, Oakley JR, Lavery IC.* Ripstein procedure is an effective treatment for rectal prolapse without constipation. *Dis Colon Rectum* 1993; 36: 501–507.
10. *Speakman CT, Maden MV, Nicholls RJ, Kamm MA.* Lateral ligament division during rectopexy causes constipation but prevents recurrence: results of a prospective randomised study. *Brit J Surgery* 1991; 78: 1431–1433.
11. *Kim DS, Tsang CBS, Wong WD, Lowry AC, Goldberg SM, Madoff RD.* Complete rectal prolapse: evolution of management and results. *Dis Colon Rectum* 1999; 42: 460–469.
12. *Williams JG, Wong WD, Jensen LL, Rothenberger DA, Goldberg SM.* Incontinence and rectal prolapse: a prospective manometric study. *Dis Colon and Rectum* 1991; 34: 209–16.
13. *Farouk R, Duthie GS, Bartolo DC, MacGregor AB.* Restoration of continence following rectopexy for rectal prolapse and recovery of internal anal sphincter electromyogram. *Brit J Surgery* 1992; 79: 439–440.
14. *Bartolo DC, Duthie GS.* The physiological evaluation of operative repair for incontinence and prolapse. *Ciba Found Symp* 1990; 151: 223–245.
15. *Novell J, Osborne M, Winslet M, Lewis A.* Prospective randomized trial of Ivalon sponge rectopexy versus sutured rectopexy for full-thickness rectal prolapse. *Brit J Surgery* 1994; 81: 904–906.
16. *Madoff RD, Malgren A.* One hundred years of rectal prolapse surgery. *Dis Colon and Rectum* 1999; 42: 441–450.
17. *Čapov I, Wechsler J, et al.* Drény. Jejich využití v chirurgických oborech [Drains. Their utilisation in surgical disciplines]. Praha: Grada, 2001. 190 pp, ISBN 80–247–0228–2.
18. *Veverková L, Kalač J, Žák J, Mašek M, Mach P.* Hojení chronických ran [Healing of chronic wounds]. *Zdravotnické noviny* 2000; 49 (4): 10–11.
19. *Vávra P, Zonča P, Faltýn J, Kopecký J.* Operative treatment of haemorrhoids in Czech Republic at the end of the second millennium. Joint Meeting of the Mediterranean Society of Coloproctology and the Israel Society of Colon and Rectal Surgery, Nasareth, Israel, 2000. Book of Abstracts.

